대한정위기능신경외과학회지
JKSFN
Journal of the
Korean Society of Stereotactic and Functional Neurosurgery

Clinical Article

pISSN 1738-6217 • eISSN 2765-6608
J Korean Ster Func Neurosurg 2021;17(2):97-102
https://doi.org/10.52662/jksfn.2021.00108

Received: August 29, 2021
Revised: September 15, 2021
Accepted: September 15, 2021

Address for correspondence:
Kyung Rae Cho, MD
Department of Neurosurgery, Konkuk University Medical Center, Konkuk University School of Medicine, 120-1 Neungdong-ro, Gwangjin-gu, Seoul 05030, Korea
Tel: +82-2-2030-7357
Fax: +82-2-2030-8138
E-mail: medicasterz@gmail.com
ORCID: https://orcid.org/0000-0003-2926-3958

Clinical characteristics of patients with young-onset hemifacial spasm: a retrospective analysis of 151 cases

Bongmin Jung, MD, Sang-Ku Park, MS, Kyung Rae Cho, MD, Kwan Park, MD

Department of Neurosurgery, Konkuk University Medical Center, Konkuk University School of Medicine, Seoul, Korea

Objective: The average age of hemifacial spasm (HFS) onset is mostly between the fifth and sixth decades of life, with a relatively low incidence in younger age groups. The objective of this study was to analyze the characteristics and clinical outcomes of young-onset hemifacial spasm (YOHFS).

Methods: Between April 1997 and March 2021, 151 HFS patients aged 30 years or younger at the time of microvascular decompression (MVD) were selected. We analyzed their epidemiological characteristics, intraoperative findings, improvements, and postoperative complications by reviewing medical records.

Results: This study included 151 patients who underwent MVD. The average age of the patients was 26 years. The mean symptom duration was 36.5 months. The male-to-female sex ratio was 1:1.5. The most common offending vessel was the anterior inferior cerebellar artery, and the most common compression type was the arachnoid type. Improvements in spasm after MVD were seen in 96.7% of patients. No permanent facial palsy was noted after MVD. Changes in brainstem auditory-evoked potentials were recorded in 11 patients; however, no permanent hearing loss was observed.

Conclusion: The characteristics and clinical outcomes of YOHFS in this study were similar to those of patients with HFS in the general population. Based on the clinical outcomes, MVD for YOHFS is effective and safe. Therefore, MVD should be considered in patients with YOHFS.

KEY WORDS: Hemifacial spasm, Microvascular decompression surgery, Prevalence

INTRODUCTION

Hemifacial spasm (HFS) is a neuromuscular movement disorder characterized by brief or persistent involuntary contractions of the muscles innervated by the facial nerve [1]. The exact pathophysiology of HFS remains unclear, but two hypotheses have been discussed. In the peripheral hypothesis, the compression of nerve fibers by adjacent vessels may transmit abnormal nerve signals and cause HFS [2]. The central hypothesis explains that HFS is created by vessel compression to the facial nucleus on the brainstem; then, the backfiring signal (antidromic nerve conduction) might stimulate the facial nerve to cause spasm [3]. Except in cases of secondary HFS caused by trauma, demyelinating disorders, tumors, and

infections [4], it is believed that the cause of HFS is chronic compression of adjacent vessel to the root exit zone (REZ) of the facial nerve [5]. The average age of HFS is mostly between the 5th and 6th decades of life [1,6] but a lower incidence is reported in those aged 30 years and under [7-9]. Since only a few studies on young-onset hemifacial spasm (YOHFS) have been reported, little is known. Because chronic nerve influences may cause HFS, the pathophysiology of YOHFS may be different from that of typical HFS. We analyzed the characteristics of 151 patients with YOHFS, which is, to the best of our knowledge, the largest cohort reported to date.

MATERIALS AND METHODS

A total of 4,363 patients underwent microvascular decompression (MVD) surgery for HFS between April 1997 and March 2021. Among them, 151 patients were aged 30 years or younger at the time of surgery (3.5%). The diagnosis was made based on clinical history, physical examination, and radiologic findings. All patients underwent magnetic resonance imaging to identify vessel compression at the facial nerve REZ.

The assessment was performed by reviewing the medical records. The present study protocol was reviewed and approved by the Institutional Review Board of Konkuk University Medical Center (approval No. 2021-08-002). The patients' sex, age, duration of symptoms at the time of surgery, past medical history, severity of the symptoms, improvement of spasms, changes in lateral spread response (LSR) during surgery, type of compression, changes in brainstem auditory-evoked potential (BAEP), facial nerve indentation, and offending vessels were analyzed. Postoperative complications were also analyzed.

The severity of HFS was categorized into four different groups, as described in a previous report [10]. Grade 1 patients complained of localized spasms around the periocular area. Grade 2 patients showed involuntary movement spreading to other parts of the ipsilateral face and with the orbicularis oris, zygomaticus, frontalis, or platysma muscle affected. Grade 3 patients experienced interference with vision because of frequent tonic spasms. Grade 4 patients had disfiguring asymmetry and continuous contraction of the orbicularis oculi muscles affecting the opening of the eye.

Facial electromyography and BAEP were monitored throughout the surgery to detect injury to the 7th and 8th nerves. The changes in the amplitude and latency of BAEP were continuously reported to the operator by an expert neurophysiologist. The LSR was monitored to evaluate successful MVD. We categorized the LSR changes into five types: Type 1A (disappearance of the LSR after opening of the dura), 1B (LSR loss after cerebrospinal fluid [CSF] drainage), 2A (LSR loss immediately after MVD), 2B (delayed LSR loss after MVD), or 3 (no signal change after MVD).

Compression types were categorized into six groups. In the arachnoid type, arachnoid trabeculae between the vessel and the brainstem cause the vessel to be tightly tethered to the facial nerve. In the branched type, the facial nerve is caught between the compressing vessel and its branch. In the perforator type, perforating arteries from the compressing vessel cause compression by tethering the vessel to the brainstem. In the loop type, the vascular loop of the offending vessel compresses the facial nerve. In the sandwich type, the facial nerve is sandwiched between two different vessels. In the tandem type, one vessel compresses another vessel, which in turn compresses the nerve [5,11].

The indentation of the facial nerve compression by the offending vessels was analyzed under a microscope and categorized into three groups: grade 1 (minimal or no indentation of the facial nerve), grade 2 (moderate indentation), or grade 3 (severe indentation causing discoloration of the facial nerve) [5].

The improvement in spasm after MVD was categorized into three groups by the degree of the disappearance of spasm and was evaluated immediately post-operation, at a 1-month follow-up, and at a 1-year follow-up. Group 1 comprised patients with complete disappearance of spasm, group 2 comprised those whose symptoms remained under 50% compared to the preoperative state, and group 3 comprised those who remained ≥50% symptomatic or even had aggravation of symptoms after surgery.

RESULTS

Demographics of young-onset hemifacial spasm

The mean patient age was 26±3.6 years (range, 7–30 years). The average duration of symptoms before surgery was 36.5±24.9 months (range, 5–174 months). The male-to-female ratio was 1:1.5 (n=61 [40.4%]:n=90 [59.6%]). Right-sided HFS was observed in 81 patients (53.6%) and left-sided in 70 patients (46.4%). Grade 2 spasm was most frequent (n=94; 62.3%), followed by grade 3 (n=42; 27.8%), grade 1 (n=11; 7.3%), and grade 4 (n=4; 2.6%). Seven patients had a history of hypertension (4.6%), and one patient had diabetes mellitus. These demographic data is summarized at Table 1.

Intraoperative findings in young-onset hemifacial spasm

Every patient had a clear offender compressing the facial nerve REZ. The offending vessels and their compression type and facial nerve indentation grades were confirmed under a microscope. There were 107 cases (70.9%) with only the anterior inferior cerebellar artery (AICA) as the offender, 20 cases (13.2%) with only

 https://doi.org/10.52662/jksfn.2021.00108

Table 1. Demographic data of patients with young-onset hemifacial spasm

Characteristic of young patient	Subheading	Value
Age at surgery (yr)		26 ± 3.6 (7–30)
Symptom duration before surgery (mo)		36.5 ± 24.9 (5–174)
Sex	Male	61 (40.4)
	Female	90 (59.6)
Left:right (ratio)		70 (46.4):81 (53.6)
Severity of spasm	Grade 1	11 (7.3)
	Grade 2	94 (62.3)
	Grade 3	42 (27.8)
	Grade 4	4 (2.6)
Past medical history	Diabetes mellitus	1 (0.7)
	Hypertension	7 (4.6)

Values are presented as mean±standard deviation (range) or number (%).

the posterior inferior cerebellar artery (PICA), 1 case (0.7%) with only the vertebral artery (VA). Multiple offenders were seen in 23 cases (15.2%), including the AICA and PICA in 3 cases, the AICA and VA in 8 cases, the PICA and VA together in 4 cases, multiple vessels including veins in 7 cases, and the AICA, PICA, and VA together in 1 case.

The arachnoid type was the most common type (n = 57; 37.7%), followed by perforator type (n = 42; 27.8%), tandem type (n = 20; 13.2%), branched type and sandwich type (both n = 12; 7.9% each), and loop type (n = 8; 5.3%). Grade 1 indentations were observed in 20 patients (13.2%), grade 2 in 59 patients (39.1%), and grade 3 in 72 patients (47.7%).

BAEP changes were found in 11 patients of whom 8 had full recovery and 3 showed recovery under 50% during surgery. However, no postoperative hearing loss was observed.

Disappearance of LSR after decompression of the offender from the facial nerve, type 2A disappearance of spasm was the most common type (n = 105; 69.5%). Type 1A was observed in 25 patients (16.6%), type 2B in 14 patients (9.3%), type 1B in 5 patients (3.3%), and type 3 in 2 patients (1.3%). These intraoperative findings are organized at Table 2.

Table 2. Intraoperative findings of YOHFS patients

Intraoperative finding of YOHFS	Subheading	Value
Offending vessels	AICA	107 (70.9)
	PICA	20 (13.2)
	VA	1 (0.7)
	Multiple offenders	23 (15.2)
Compression type	Arachnoid	57 (37.7)
	Branched	12 (7.9)
	Perforator	42 (27.8)
	Loop	8 (5.3)
	Sandwich	12 (7.9)
	Tandem	20 (13.2)
Indentation	Grade 1	20 (13.2)
	Grade 2	59 (39.1)
	Grade 3	72 (47.7)
LSR changes	1A	25 (16.6)
	1B	5 (3.3)
	2A	105 (69.5)
	2B	14 (9.3)
	3	2 (1.3)

Values are presented as number (%). YOHFS: young-onset hemifacial spasm, AICA: anterior inferior cerebellar artery, PICA: posterior inferior cerebellar artery, VA: vertebral artery, LSR: lateral spread response.

Improvement of spasms after the surgery

In the immediate postoperative period, there were 103 patients (68.2%) in group 1, 45 (29.8%) in group 2, and 3 (2.0%) in group 3. One month after surgery, group 1 increased to 118 patients (78.1%), group 2 decreased to 23 (15.2%), and group 3 increased to 10 (6.6%). At the 1-year follow-up, there were 146 patients (96.7%) in group 1, 3 (2.0%) in group 2, and 2 (1.3%) in group 3. This gradual increase of improvement is depicted at Fig. 1.

Among patients with spasm relief at immediate postoperative, 7 aggravated to grade 2 and 3 after a month. However, they all became spasm free at 1 year follow-up. Forty-three patients who showed grade 2 outcome immediately, 39 patients were improved to grade 1 at the 1 year follow-up whereas the three patients remained as grade 2 and one patient aggravated to grade 3 at 1 year follow-up. Among 3 who were grade 3 immediate postoperative, one patient stayed as grade 3 at 1 year follow-up and the other 2 patients improved to grade 1 at 1 year follow-up. Finally, 146 patients were spasm free (96.7%) at one year follow-up visit.

Forty-three patients visited the outpatient clinic even one year after the surgery. The follow-up period was from 3 years to 16 years after the surgery. The longest follow-up period patient was

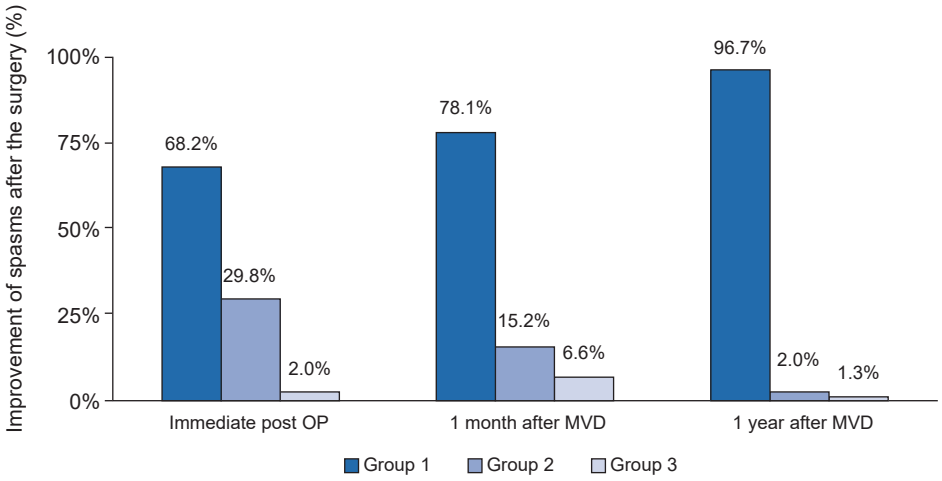

Fig. 1. Improvement of spasms after microvascular decompression (MVD) in young-onset hemifacial spasm. The number of group 1 patients gradually increased. In the immediate postoperative (post OP) period, there were 105 patients (69.5%) in group 1. Group 1 increased to 118 patients (78.1%) at 1 month after MVD and to 146 patients (96.7%) at the 1-year follow-up. The number of group 2 patients declined. In the immediate postoperative period, it included 43 patients (28.5%). The number of group 2 patients decreased to 23 (15.2%) at the 1-month follow-up and 3 (2.0%) at the 1-year follow-up. Only 3 patients were classified as group 3 in the immediate postoperative period. However, at 1 month after MVD, the number of group 3 patients increased to 10 (6.6%). At the 1-year follow-up, the number of group 3 patients decreased to 2 (1.3%).

28-year-old female at the time of the surgery and she did not show any recurrence at the last follow-up.

Forty-two patients were patients who had grade 1 spasm one year after the surgery. Most patients had no recurrence. Although few patients had minimal recurrence, they showed improvements at the next follow-up. One patient was the patient who had grade 2 spasm one year after the surgery. The patient showed improvement of the spasm at 2 year follow-up. While the other two grade 2 patients and the two grade 3 spasm patients did not visit the outpatient clinic after one year. We have analyzed multiple factors such as duration of symptom, age of surgery, indentation grades with prognosis. However there was no significant factor.

We have analyzed multiple factors such as duration of symptom, age of surgery, indentation grades to evaluate the prognosis of the MVD. However, there was no significant factor.

Complications

There were 3 patients with CSF leak, 2 with meningitis, and 18 with facial palsy immediately after surgery. Excluding 2 patients who already had facial palsy before MVD, 18 patients had facial palsy after surgery (12.1%). There were 9 patients with House-Brackmann grade 2 facial palsy, 8 with grade 3, and 1 with grade 4. All patients with facial palsy recovered to normal by the last follow-up. Transient hearing loss was found in 1 patient but recovered after 3 days.

DISCUSSION

We find five previous studies in the literature of patients with YOHFS who underwent MVD in PubMed search [7,8,12-14]. Two studies included 10 or less than 10 patients and largest cohort reported by Chang et al. [8] included 33 patients. All five studies examined the number of patients, sex, age of onset or age at surgery, sides of HFS, surgical outcome and the most common offending vessels. Those previous reported literatures are summarized in Table 3.

We have found some common features of YOHFS through comparison with these other studies. Female predominance was found in three published studies and in our study (male-to-female ratio, 1:1.5). However, Jho and Jannetta [7] showed an equal male-to-female ratio, and Karki et al. [13] showed male predominance. Their studies had small patient groups of 10 and 6, respectively. Regarding the size of the patient groups, we could assume that YOHFS has female predominance as well as HFS in the general population. However, the overall male-to-female ratio reported in other studies shows a more definite female predominance (1:1.9–2.4) [5,15,16] but YOHFS shows a more balanced male-to-female ratio. These sex differences in YOHFS and HFS in the general population might be because HFS is a facial muscle disorder related to facial expressions and cosmetic issues; as women tend to be more interested in their cosmetic appearance, they may be more likely to visit a clinic regarding facial muscle disorders than men.

 https://doi.org/10.52662/jksfn.2021.00108

Table 3. The epidemiology of young-onset hemifacial spasm

Study	Patient (n)	Sex (M:F)	Age (yr)*	Side of HFS (L:R)	Mean duration†	Outcome	Offending vessel
Jho and Jannetta (1987) [7]	10	1:1	16.5 (2–20): age of onset 26.5 (13–57): age at surgery	1:0.67	N/A	90%	PICA
Chang et al. (2001) [8]	33	1:2.3	21.5 ± 0.6 (11–25): age of onset 27.1 ± 0.5 (21–30): age at surgery	1:1.2	5.5 ± 0.6 yr	90.9% (good and fair)	PICA
Tan and Chan (2006) [12]	15	1:4	31.6 ± 4.9 (21–36): age of onset	1:0.5	4 ± 2.4 yr	-	AICA
Liang et al. (2014) [14]	16	1:3	16.3 (11–18): age of onset 24.4 (13–36): age at surgery	1:1.3	8.2 yr (1–18 yr)		AICA
Karki et al. (2019) [13]	6	1:0.5	27.8 ± 1.8 (23–30): age at surgery	1:5		100%	PICA
Our study	151	1:1.5	26 ± 3.6 (7–30): age at surgery	1:1.2	36.5 ± 24.9 mo	96.7%	AICA

M: male, F: female, HFS: hemifacial spasm, L: left, R: right, N/A: not available, PICA: posterior inferior cerebellar artery, AICA: anterior inferior cerebellar artery. *Values are presented as median (range) or mean±etandard deviation (range). †Values are presented as mean±standard deviation or median (range).

According to Singh et al. [17], the decline in estrogen and progesterone levels is related to peripheral neuropathy. Postmenopausal patients with peripheral neuropathy had lower estrogen and progesterone levels than postmenopausal patients without peripheral neuropathy. In addition, Suzuki et al. [18] reported that estrogen plays a role in neuroprotection. Estrogen protects against cell death during cerebral ischemia and influences cell proliferation. Thus, the role of hormone changes in aging females can also increase the incidence of female patients with HFS in the general population compared to YOHFS. In other words, hormonal decrease in post-menopausal patients could be the related with the fact that female prevalence of YOHFS patients is lower than the general population.

The results of MVD for HFS in the general population were similar to those for YOHFS. In a meta-analysis by Holste et al. [19], 39 studies and 6,249 patients were meta-analyzed with an overall cure rate of 90.5% at a mean follow-up of 1.25 years. This is similar to the outcomes of YOHFS studies. Therefore, we could infer that MVD is an effective treatment in young patients as well as in the general population.

Jo et al. [20] reported that 7 out of 331 patients (2.1%) experienced intraoperative BAEP changes and 2 patients had permanent hearing loss after MVD (0.6%). In our study, 11 patients had intraoperative BAEP changes (7.3%). However, none of the patients experienced hearing loss after surgery, regardless of BAEP improvement during surgery. One patient who had transient hearing loss without intraoperative BAEP changes fully recovered 3 days after surgery. There were more frequent BAEP changes in YOHFS than in previous studies, which might be related to the fact that the brain volume of younger patients is larger than that in older patients, and the CSF space is relatively small [21]. Therefore, more retraction of the cerebellum might be needed in young patients, and consequently, BAEP changes can be more frequently found. Nevertheless, nerve fibers might be more durable in younger patients and no hearing loss was found in younger patients, even though there were more BAEP changes. This might be related with the previous studies which showed that neuroplasticity of young population is more active compared with older population [22,23].

The incidence of postoperative facial palsy can be explained in the same fashion. According to a systematic review of 5,685 patients by Miller and Miller [24], permanent postoperative facial palsy occurred in 0.9% of patients after MVD. However, the young patients in our group showed no permanent facial palsy and showed only transient facial palsy. Although hearing loss or facial palsy after MVD is infrequent, the results of this study may be biased; further studies are needed to confirm these hypotheses.

The offending vessels and the type of compression in YOHFS were similar with the general population. As we previously reported that AICA (53.2%) was the most common offender and the PICA (30.9%) as the second most common offending vessel [5]. For type of compression, YOHFS as well as previous reported studies showed dominant ratio of arachnoid type.

The limitations of our study are that it included data from only patients with YOHFS and lacked data from patients in the general population with HFS. The comparative study of our group and the general population relies on a comparison with previous reports. Therefore, statistical analysis between patients with YOHFS and those in the general population with HFS should be performed to confirm our conclusions.

CONCLUSION

The pathophysiology of HFS remains unclear. However, the pathophysiology of YOHFS seems to be similar to HFS in the gen-

eral population, considering that there was no significant difference between YOHFS and the general population. The clinical outcomes of MVD for YOHFS were satisfactory. In addition, complications such as facial palsy and hearing loss are relatively rare. Therefore, MVD should be considered as the treatment of choice for YOHFS.

CONFLICTS OF INTEREST

No potential conflict of interest relevant to this article was reported.

REFERENCES

1. Rosenstengel C, Matthes M, Baldauf J, Fleck S, Schroeder H. Hemifacial spasm: conservative and surgical treatment options. Dtsch Arztebl Int 2012;109:667-73
2. Gardner WJ. Cross talk--the paradoxical transmission of a nerve impulse. Arch Neurol 1966;14:149-56
3. Ferguson JH. Hemifacial spasm and the facial nucleus. Ann Neurol 1978;4:97-103
4. Colosimo C, Bologna M, Lamberti S, Avanzino L, Marinelli L, Fabbrini G, et al. A comparative study of primary and secondary hemifacial spasm. Arch Neurol 2006;63:441-4
5. Hyun SJ, Kong DS, Park K. Microvascular decompression for treating hemifacial spasm: lessons learned from a prospective study of 1,174 operations. Neurosurg Rev 2010;33:325-34; discussion 334
6. Park JS, Lee S, Park SK, Lee JA, Park K. Facial motor evoked potential with paired transcranial magnetic stimulation: prognostic value following microvascular decompression for hemifacial spasm. J Neurosurg 2018;131:1780-7
7. Jho HD, Jannetta PJ. Hemifacial spasm in young people treated with microvascular decompression of the facial nerve. Neurosurgery 1987;20:767-70
8. Chang JW, Chang JH, Park YG, Chung SS. Microvascular decompression of the facial nerve for hemifacial spasm in youth. Childs Nerv Syst 2001;17:309-12
9. Kobata H, Kondo A, Kinuta Y, Iwasaki K, Nishioka T, Hasegawa K. Hemifacial spasm in childhood and adolescence. Neurosurgery 1995;36:710-4
10. Lee JA, Jo KW, Kong DS, Park K. Using the new clinical grading scale for quantification of the severity of hemifacial spasm: correlations with a quality of life scale. Stereotact Funct Neurosurg 2012;90:16-9
11. Jeon CJ, Kong DS, Lee JA, Park K. The efficacy and safety of microvascular decompression for hemifacial spasm in elderly patients. J Korean Neurosurg Soc 2010;47:442-5
12. Tan EK, Chan LL. Young onset hemifacial spasm. Acta Neurol Scand 2006;114:59-62
13. Karki P, Yamagami M, Takasaki K, Bohara M, Hosoyama H, Hanada T, et al. Microvascular decompression in patients aged 30 years or younger. Asian J Neurosurg 2019;14:111-7
14. Liang J, Guo Z, Zhang L, Yu Y. Adolescent-onset idiopathic hemifacial spasm. Neurol India 2014;62:175-7
15. Nilsen B, Le KD, Dietrichs E. Prevalence of hemifacial spasm in Oslo, Norway. Neurology 2004;63:1532-3
16. Traylor KS, Sekula RF, Eubanks K, Muthiah N, Chang YF, Hughes MA. Prevalence and severity of neurovascular compression in hemifacial spasm patients. Brain 2021;144:1482-7
17. Singh A, Asif N, Singh PN, Hossain MM. Motor nerve conduction velocity in postmenopausal women with peripheral neuropathy. J Clin Diagn Res 2016;10:CC13-6
18. Suzuki S, Brown CM, Wise PM. Mechanisms of neuroprotection by estrogen. Endocrine 2006;29:209-15
19. Holste K, Sahyouni R, Teton Z, Chan AY, Englot DJ, Rolston JD. Spasm freedom following microvascular decompression for hemifacial spasm: systematic review and meta-analysis. World Neurosurg 2020;139:e383-90
20. Jo KW, Lee JA, Park K, Cho YS. A new possible mechanism of hearing loss after microvascular decompression for hemifacial spasm. Otol Neurotol 2013;34:1247-52
21. Sakka L, Coll G, Chazal J. Anatomy and physiology of cerebrospinal fluid. Eur Ann Otorhinolaryngol Head Neck Dis 2011;128:309-16
22. Clarkson C, Antunes FM, Rubio ME. Conductive hearing loss has long-lasting structural and molecular effects on presynaptic and postsynaptic structures of auditory nerve synapses in the cochlear nucleus. J Neurosci 2016;36:10214-27
23. Goldsworthy MR, Rogasch NC, Ballinger S, Graetz L, Van Dam JM, Harris R, et al. Age-related decline of neuroplasticity to intermittent theta burst stimulation of the lateral prefrontal cortex and its relationship with late-life memory performance. Clin Neurophysiol 2020;131:2181-91
24. Miller LE, Miller VM. Safety and effectiveness of microvascular decompression for treatment of hemifacial spasm: a systematic review. Br J Neurosurg 2012;26:438-44